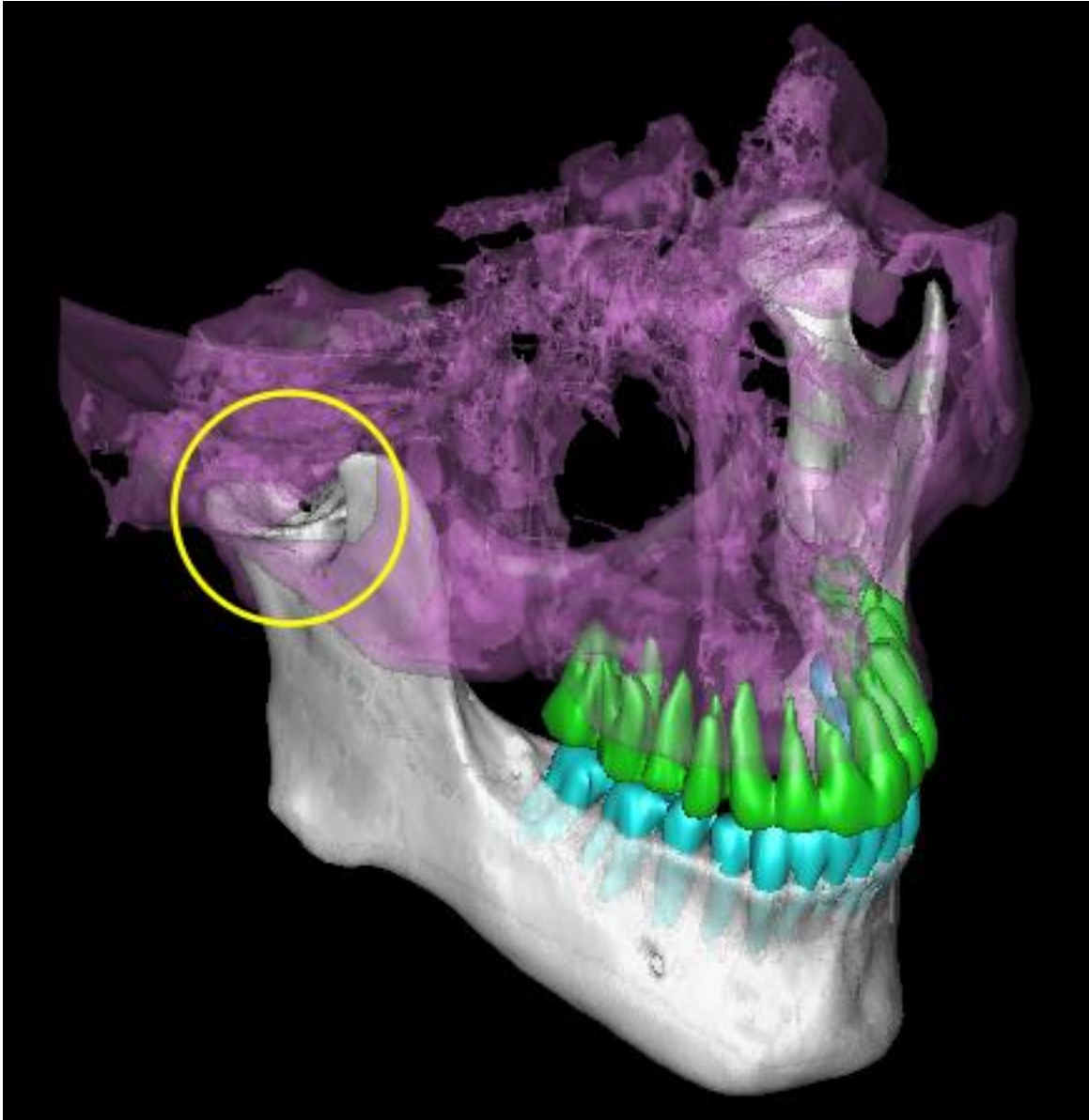
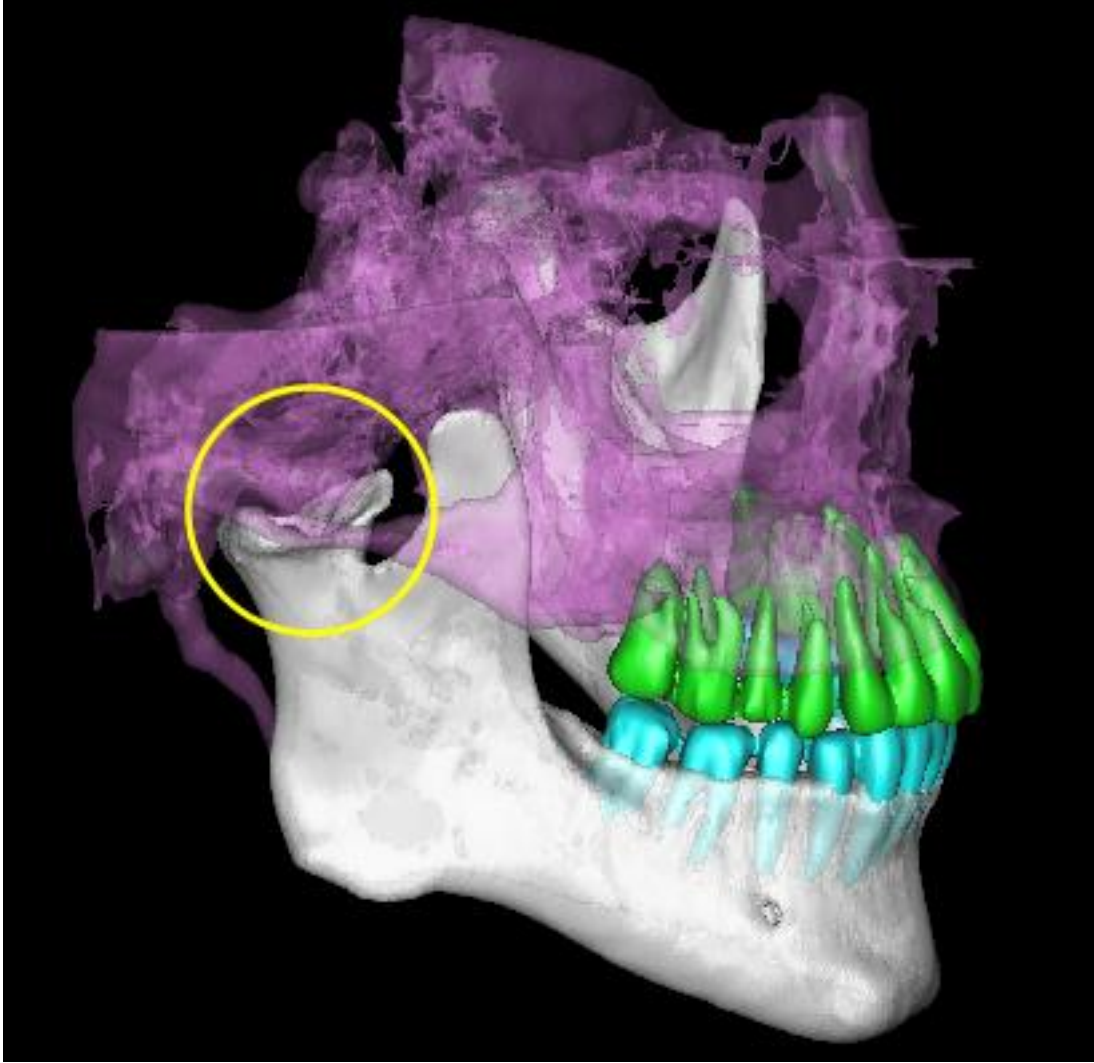


## A Strange Case of Condylar Remodeling

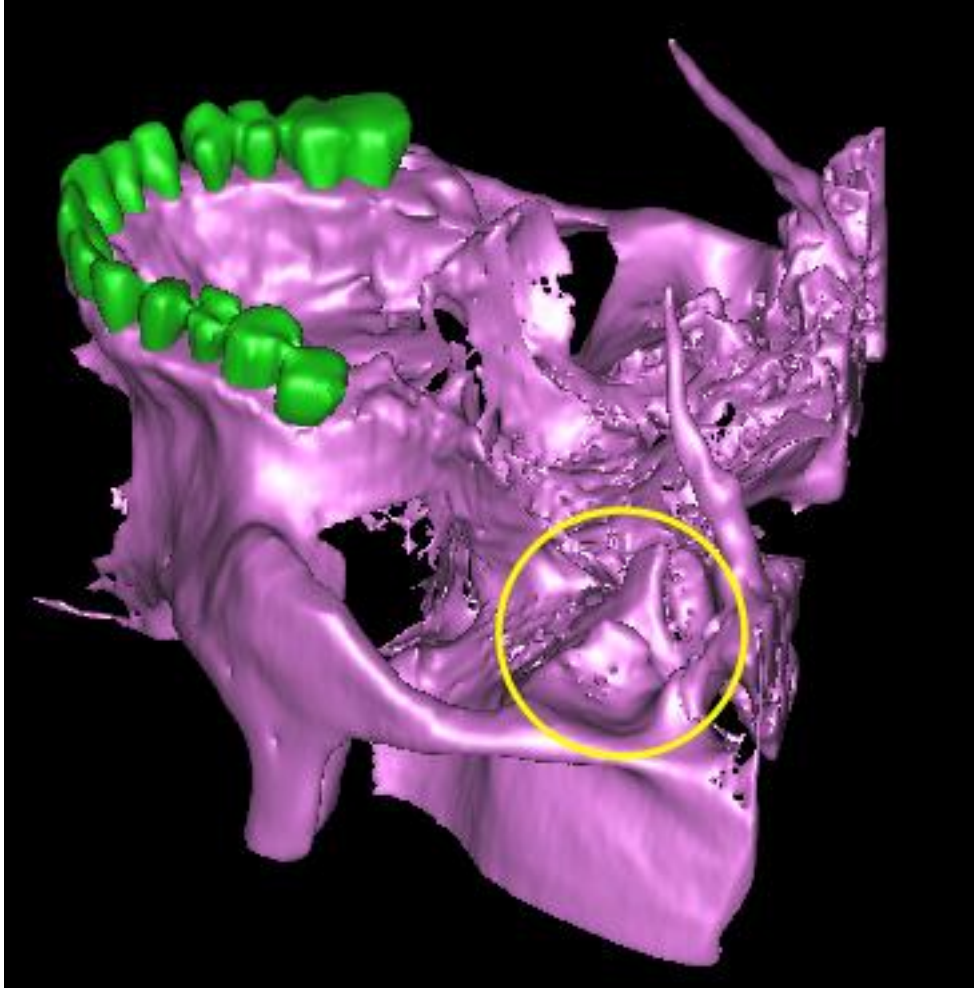
This is a strange case of condylar remodeling in the right TMJ. The following 3D reconstructions were contributed by 3D Diagnostix, Inc.



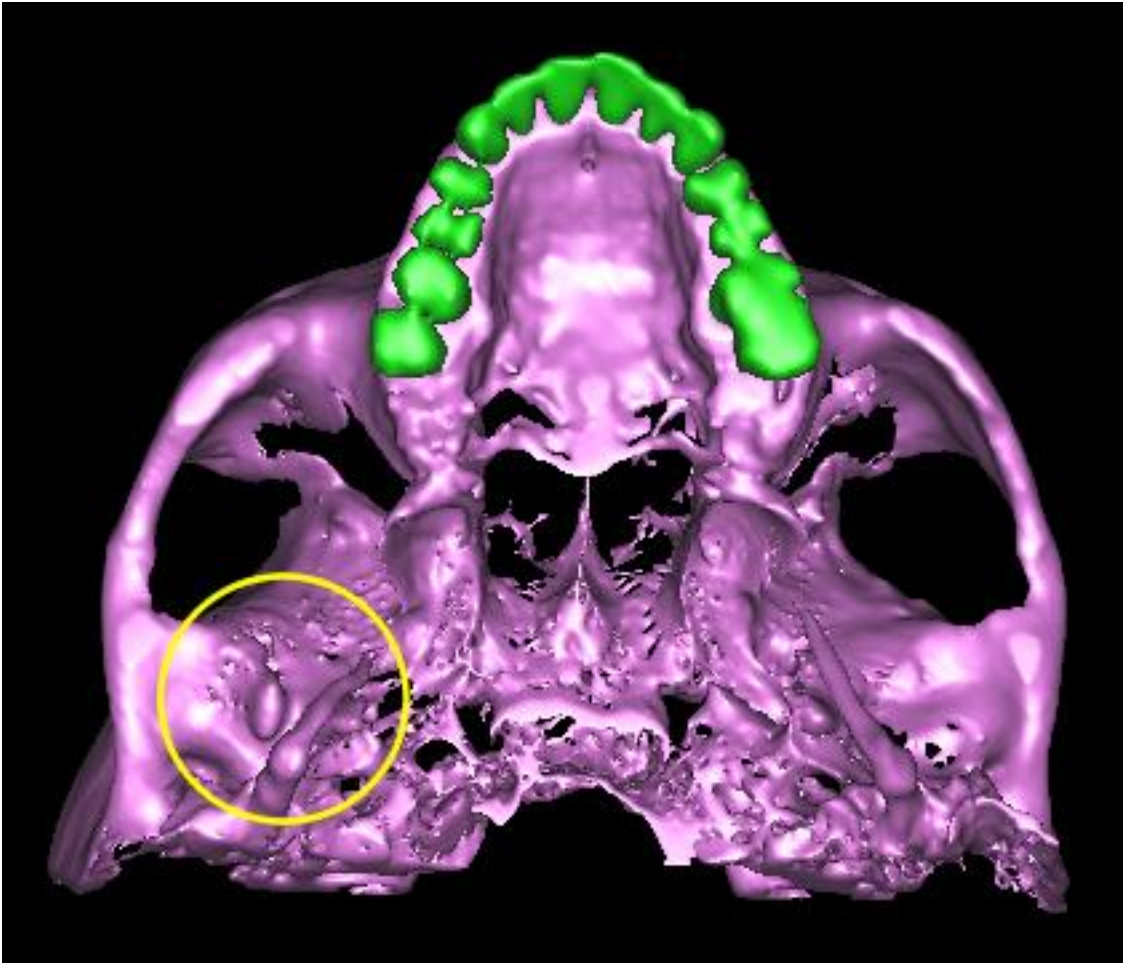
**3D Isometric View**



**3D Right Side View**



**3D Reverse Isometric view**



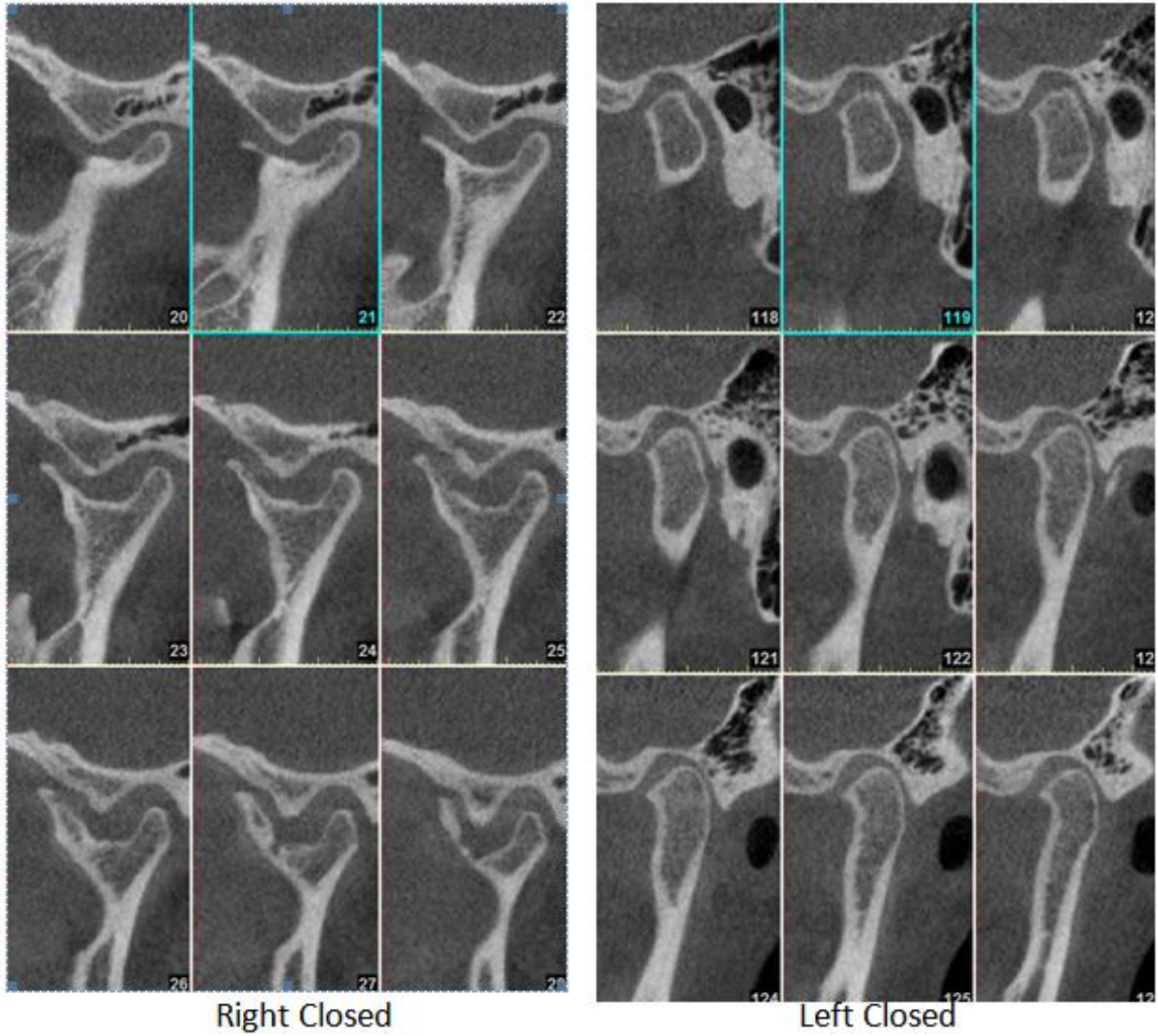
### 3D Inferior View

#### **Right TMJ Closed:**

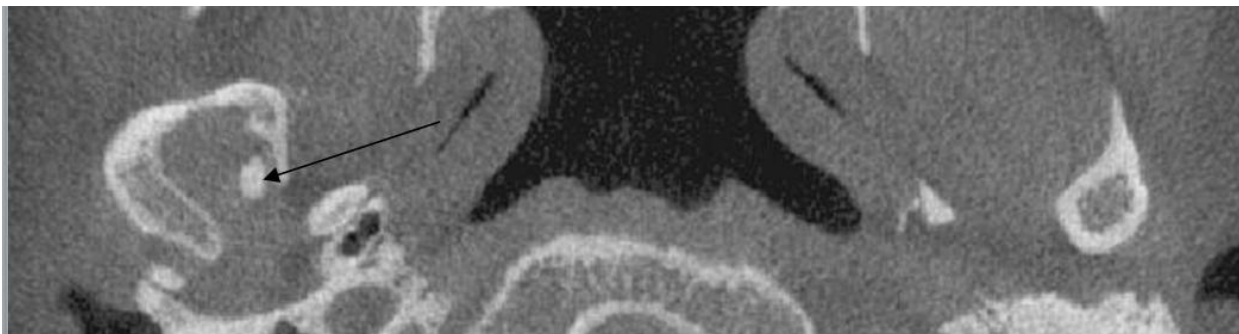• **Condyle:** Severe remodeling of the condyle showing anterior, medial and lateral osteophyte formation. The morphology of the superior aspect of the condyle appears to be following the contours of the bony growth coming from the medial aspect of the roof of the glenoid fossa.

• **Joint space:** The joint space appears to be widening in the areas of erosion. Soft tissue components cannot be evaluated using CBCT.

• **Fossa:** There seems to be a large, well-corticated bony protrusion with a central medullary area seen extending from the medial aspect of the glenoid fossa. This appears to be indenting the medial aspect of the condyle. No expansion or thinning of the cortices of the roof of the fossa can be seen corresponding with the indentation of the condyle, which suggests that the remodeling of the condyle is perhaps not occurring due to neoplastic changes within the joint space.



**Cross-Section Comparison of Left & Right TMJs**



**Axial View**

The arrow points to the bony protrusion from the Glenoid Fossa

The findings in the right TMJ are suggestive of either an osteoma from the medial aspect of the glenoid fossa extending downwards into the joint space and causing remodeling of the condyle or long term degenerative remodeling of the condyle, possibly due to past acute or continuous chronic (occlusal?) trauma). The erosion and condylar osteophyte formation in addition to this marked remodeling are suggestive of severe DJD. Internal derangement cannot be evaluated using CBCT imaging.

*Dania Tamimi, BDS, DMSc,  
Diplomate, American Board of Oral and Maxillofacial Radiology*